

ANATOMY AND DISEASES OF THE SPINE

*G'affarova Ruxshona Xamidillo qizi**Kokand University Andijan branch
Faculty of Medicine treatment direction group 206*

Abstract: This article provides information on the anatomical structure of the spine, its main sections, functional significance, and its role in human movement. Additionally, it analyzes the most common spinal diseases, their causes, clinical symptoms, and treatment methods. The article is beneficial for healthcare professionals and students, highlighting the essential principles for maintaining spinal health.

Keywords: spine, vertebra, intervertebral disc, scoliosis, osteochondrosis, anatomical structure, spinal diseases, lordosis, kyphosis, musculoskeletal system.

The spine is the central structure of the human skeletal system, providing movement, weight distribution, and protection for internal organs while working closely with key elements of the nervous system. Composed of 33–34 vertebrae connected by intervertebral discs, ligaments, and muscles, it ensures mechanical stability of the body. This article provides a detailed overview of the anatomy of the spine, its major sections, functions, and common diseases.

The spine is divided into five main sections, each with distinct anatomical features and functions:

1. Cervical region (Pars Cervicalis). Consists of 7 vertebrae (C1–C7). C1 (Atlas) supports the head and facilitates movement along the transverse axis. C2 (Axis) enables head rotation.

This is the smallest and most mobile part of the spine.

Functions: Allows head movement. Protects nerves and blood vessels in the neck region.

2. Thoracic region (Pars Thoracica). Comprises 12 vertebrae (T1–T12). Connected to the rib cage, with each vertebra articulating with ribs. Limited mobility but high structural stability.

Functions: Protects vital organs such as the heart and lungs. Assists in respiration.

3. Lumbar region (Pars Lumbalis). Consists of 5 large vertebrae (L1–L5).

Built for bearing significant weight, with a strong and dense structure. Highly mobile compared to other regions.

Functions: Facilitates lower back movements. Distributes weight between the upper body and legs.

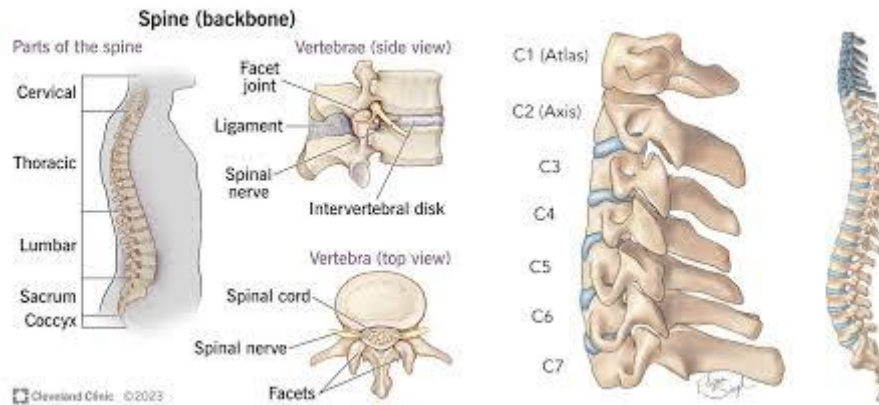
4. Sacral region (Pars Sacralis). Made up of 5 fused vertebrae (S1–S5) forming the sacrum. Connects to the pelvic bones.

Functions: Supports and protects pelvic organs. Serves as a point of attachment for the lower limbs.

5. Coccygeal region (Pars Coccygea). Consists of 4–5 rudimentary vertebrae.

A vestigial structure remaining from human evolution.

Functions: Acts as an attachment point for muscles and ligaments. Helps maintain body stability.



Functions of the spine

1. Protective function: shields the spinal cord, nerve roots, and blood vessels.
2. Movement function: enables flexion, extension, rotation, and lateral bending.
3. Shock absorption: intervertebral discs absorb impact forces to protect vertebrae.
4. Weight distribution: distributes body weight evenly across the lower limbs.

Common spine diseases

1. Osteochondrosis

Definition: degenerative and dystrophic changes in intervertebral discs.

Causes: aging, poor posture, genetic predisposition, heavy lifting.

Symptoms: neck and lower back pain, numbness in limbs, headaches, restricted movement.

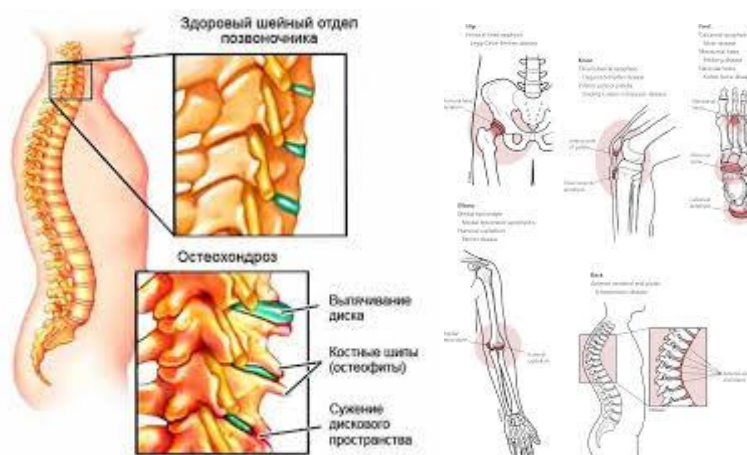
Treatment: medication (painkillers, anti-inflammatory drugs).

Physiotherapy (massage, electrotherapy). Rehabilitation exercises.

2. Scoliosis

Definition: lateral curvature of the spine. Causes: Incorrect posture, developmental defects, genetic factors. Symptoms: Asymmetrical body appearance, uneven shoulders or pelvis, movement difficulty.

Treatment: orthopedic braces. Therapeutic exercises and physiotherapy. Surgery in severe cases.



3. Kyphosis and Lordosis

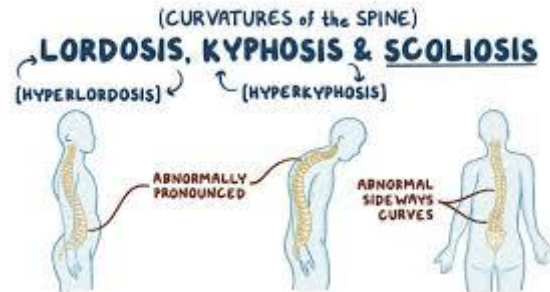
Kyphosis: excessive backward curvature of the spine.

Lordosis: excessive forward curvature of the spine.

Causes: postural issues, genetic predisposition, chronic diseases.

Symptoms: altered body shape, pain in the thoracic or lumbar region.

Treatment: physiotherapy, targeted exercises, and surgery if necessary.



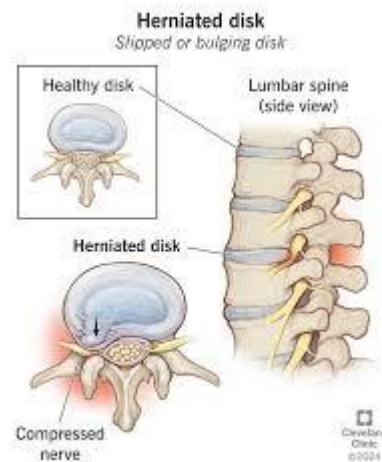
4. Herniated disc

Definition: protrusion of the inner material of an intervertebral disc through a torn outer layer.

Causes: heavy lifting, improper movements, complications of osteochondrosis.

Symptoms: sharp lower back pain, nerve root compression, numbness and weakness in the legs.

Treatment: Conservative: medications, physiotherapy. Surgical: Removal or replacement of the affected disc.

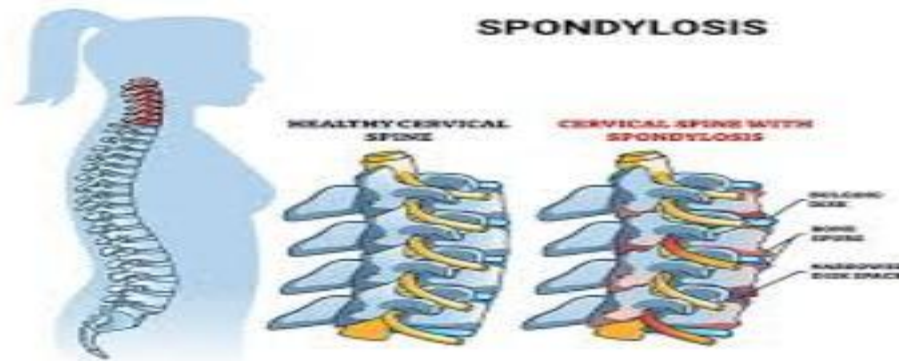


5. Spondylosis

Definition: Formation of bony outgrowths (osteophytes) and calcification in intervertebral discs.

Symptoms: Stiffness in the back, restricted movement, chronic pain.

Treatment: Physiotherapy and massage. Anti-inflammatory drugs. Surgery in advanced cases.



Conclusion

The spine is the foundation of the human skeletal system, playing a critical role in maintaining posture, enabling movement, and protecting internal organs. However, spinal diseases significantly impact an individual's quality of life. This article highlighted the anatomy, functions, and common diseases of the spine. Maintaining spinal health requires a combination of proper posture, physical activity, healthy nutrition, and regular medical checkups. Early detection and timely treatment of spinal conditions are essential to preserve mobility and overall well-being. Prioritizing spinal health is a vital step towards ensuring a healthy and active life.

References:

1. Moore, K. L., Dalley, A. F., & Agur, A. M. R. "Clinically Oriented Anatomy". Wolters Kluwer, 8th Edition, 2017.
2. Gray, H., & Standring, S. "Gray's Anatomy: The Anatomical Basis of Clinical Practice". Elsevier, 42nd Edition, 2020.
3. Bogduk, N. "Clinical Anatomy of the Lumbar Spine and Sacrum". Elsevier, 5th Edition, 2012.
4. Kapanji, I. A. "The Physiology of the Joints". Churchill Livingstone, 6th Edition, 2008.
5. White, A. A., & Panjabi, M. M. "Clinical Biomechanics of the Spine". Lippincott Williams & Wilkins, 2nd Edition, 1990.
6. Schmorl, G., & Junghanns, H. "The Human Spine in Health and Disease". Grune & Stratton, 3rd Edition, 1971.