

Khuseynova Gulshan Khuseynovna

Bukhara State Medical Institute, Department of Anatomy, Clinical Anatomy (OSTA).

COMPARATIVE DESCRIPTION OF THE MORPHOLOGICAL CHARACTERISTICS OF THE KIDNEYS ON THE 7TH AND 14TH DAYS OF THE LATE PERIOD OF MODERATE SPINAL CORD INJURY

Abstract: This article presents information on the results of scientific studies that allow us to evaluate and study the morphological features of the kidneys of 3-month-old rats after moderate to severe spinal cord injuries. Morphological analysis of the rat kidneys was performed on the 7th and 14th days after spinal cord injury.

Key words: spinal cord injury, kidneys, nephron, biopsy, Shumlyansky-Bowman capsule, vascular glomerulus.

Резюме: В данной статье представлены сведения о результатах научных исследований, позволяющих оценить и изучить морфологические особенности почек 3-месячных крыс после средне - тяжелых травм спинного мозга. Морфологический анализ почек крыс проводили на 7-е и 14-и сутки после травмы спинного мозга.

Ключевые слова: спинно-мозговая травма, почки, нефрон, биопсия, капсула Шумлянско-Боумена, сосудистый клубочек.

Abstract: In our country, many targeted measures are being implemented to radically improve the healthcare system and improve the quality of prompt and qualified medical care provided to the population [4,5,6,7,10,11,12,34,40.]. At the same time, the study of renal complications, especially extra- and intraspinal complications after spinal cord injury, which are considered one of the problems of modern nephrology today [24,29,32,33,39,41.], measures aimed at early diagnosis, prevention and treatment of the disease, and reducing mortality remain urgent problems [1,18,19, 20, 21,25,38,42]. Unfortunately, the available literature is limited in its information on the effects of different stages of spinal cord injury on renal morphology and function [2,16,17, 26,32,35,43]. This situation requires further studies to determine the role of morphological changes in the kidneys as a result of spinal cord injury [23,27,30,36,37,44.].

Materials and methods: Three-month-old white rats with an average weight of 150 g were used for this study. All laboratory animals were housed in a vivarium in plastic cages lined with wood chips at room temperature with a 12-h light-dark cycle in accordance with laboratory animal care standards. The experimental group of animals was divided into 2 groups, namely, the first group included animals without spinal cord injury (control, n=10), and the second group (experimental n=10) included animals with mild spinal cord injury and treatment. In the study, mild spinal cord injury was inflicted on white rats using a specially developed model using the "road accident" method.

During this experiment, all animals received mild to severe injuries. The surviving animals were transferred to a special plastic cage and observed until the post-traumatic state was restored.

Treatment with drugs was carried out one day after spinal cord injury, and drugs were administered intramuscularly, based on the average weight of the animals. Methylprednisolone 4 ml of solution was dissolved in 45 ml of isotonic solution of sodium chloride and the resulting mixture was injected intramuscularly from 0.3 ml, 1 ml of 25% neuromidine solution was dissolved in 45 ml of

isotonic solution of sodium chloride and 0.6 ml of the resulting mixture was injected intramuscularly from 5 ml of pentoxifylline solution in 196 ml of isotonic sodium chloride was dissolved in the solution and the resulting mixture was injected intramuscularly from 0.4 ml. Magnesium sulfate, neuroxon drug was administered intramuscularly from the 1st day after brain injury, and piracetam was administered intramuscularly from the 3rd day for 10 days. In this case, on the 1st and 3rd days after the start of drug administration, the kidneys of white outbred rats were examined in accordance with the established procedure in order to determine the morphological changes that occur in the kidney tissues after drug treatment of animals.

For histopathological comparison of the control and experimental groups, the kidneys of white rats were isolated on the 1st and 3rd days after spinal cord injury, and samples were taken and preparations were prepared to determine the morphological changes that occur in the kidney tissues. All preparations prepared using standard histological methods were stained with hematoxylin and eosin.

Research results: Macroscopically, the kidneys of 3-month-old white rats of the experimental group were reddish-brown in appearance, bean-shaped, located in the lumbar region, covered with a smooth and shiny capsule on the outside, and no pathological changes were observed in them that were visible from the macroscopic side.

Histological examination showed that a number of characteristic changes were detected in the structure of nephrons in the rat kidneys on the 1st and 3rd days after mild spinal cord injury.

The following data were obtained in a study of the kidney in 3-month-old white rats after mild spinal cord injury by drug treatment:

When the morphological and morphometric parameters of the kidneys of rats were studied one day after the start of treatment in mild spinal cord injury, the absolute weight of the kidneys was from 708.14 mg to 1009.82 mg, the average weight was 845.82 ± 31.5 mg; kidney length - from 14.5 mm to 20 mm, average length - 17.51 ± 0.5 mm; width - from 5.2 mm to 8.7 mm, average - 7.28 ± 0.3 mm; thickness - from 6.3 mm to 9.2 mm, average thickness - 7.87 ± 0.2 mm; kidney volume ranged from 322.91 mm³ to 745.31 mm³, the average was 528.61 ± 34.7 mm³.

The area of renal corpuscles ranges from 1920.8 μm^2 to 2313 μm^2 , the average is 2063.17 ± 36.7 μm^2 ; the area of the vascular ball - from 1612.82 μm^2 to 1889.2 μm^2 , average - 1711.56 ± 28.2 μm^2 ; the area of the capsule cavity ranged from 285.32 to 345.67 μm^2 , the average was equal to 314.91 ± 6.6 μm^2 .

The diameter of the proximal convoluted tubules was from 28.47 μm to 33.9 μm , the average was 31.4 ± 0.5 μm , the diameter of the tubule cavity was from 15.1 μm to 19.33 μm , the average was 17.19 ± 0.4 μm .

The diameter of the distal convoluted tubules was from 26.8 to 30.4 μm , the average was 28.24 ± 0.3 μm , the diameter of the tubule cavity was from 14.5 to 16.9 μm , the average was 15.33 ± 0.2 μm .

When the morphological and morphometric indicators of the kidneys of rats were studied three days after the start of treatment in mild spinal cord injury, the absolute weight of the kidneys was from 656.9 mg to 1005.38 mg, the average weight was 838.05 ± 31.4 mg, the kidney length was from 14.41 mm to 20.31 mm, the average length was - 17.42 ± 0.6 mm; width – from 5.94 mm to 8.5 mm, average – 6.99 ± 0.3 mm; thickness - from 7.26 mm to 8.64 mm, average thickness - 8.06 ± 0.1 mm; the volume of the kidney ranged from 343.81 mm³ to 648.71 mm³, the average was 518.01 ± 31.9 mm³.

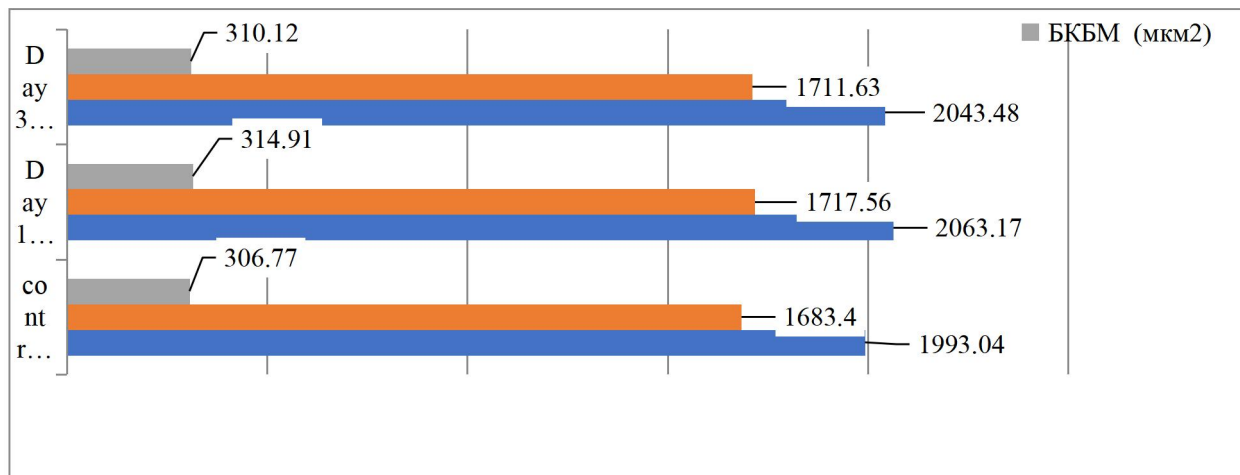


Figure 1. Comparative description of histomorphometric indicators of renal nephron elements after 1-, 3-, 7-, 14-day drug treatment in mild spinal cord injury.

The area of the kidney body is from 1922.6 μm^2 to 2287.67 μm^2 , the average is $2043.48 \pm 32.5 \mu\text{m}^2$; the area of the vascular ball - from 1608.7 μm^2 to 1789.18 μm^2 , average - $1711.63 \pm 18.9 \mu\text{m}^2$; the area of the capsule cavity ranged from 267.34 μm^2 to 336.2 μm^2 , the average was equal to $310.12 \pm 5.4 \mu\text{m}^2$.

The diameter of the proximal convoluted tubules is from 27.5 to 37.76 μm , the average is $31.36 \pm 0.8 \mu\text{m}$, the diameter of the tubular space is from 15.43 to 19.46 μm , the average is 17, It was $17 \pm 0.4 \mu\text{m}$.

The diameter of the distal convoluted tubular tubules is from 19.8 μm to 29.76 μm , the average is $28.13 \pm 0.8 \mu\text{m}$, the diameter of the tubular cavity is from 13 μm to 17.5 μm , the average is $15.31 \pm 0.8 \mu\text{m}$. It was 0.4 μm .

Thus, in the macroscopic, histological and morphometric studies conducted after drug treatment, there was no obvious macroscopic change in the kidneys of 3-month-old rats under the influence of mild brain injury of the experimental group.

Histologically, kidney bodies of nephrons, vascular balls, Shumlyansky-Bowman capsule retain their structure. From the 1st day of treatment, a decrease in interstitial swelling, a decrease in venous blood vessels, a narrowing of the enlarged capsule space, a decrease in the area of focal bleeding between the preserved ball and the proximal and distal convoluted tubules were found.

The results of histomorphometric examination showed that in rats of the experimental group treated with medicinal preparations after mild brain injury, the diameter of the Shumlyansky-Bowman capsule, the diameter of the distal convoluted tubules, and the diameter of their lumen increased from the 1st to the 3rd day of the experiment. It was observed that the parameters of the control group were close to those of the control group. The decrease in the areas of blood clotting is a clear evidence of the occurrence of recovery processes in the nephron elements.

Conclusion: Thus, the therapeutic measures taken during the experiment, starting from the acute period of mild spinal cord injury, showed their effectiveness, and the control group animals had a normal renal nephron element. morphometric parameters. Thus, these pharmacological drugs can be successfully used as an effective tool for the treatment of renal complications after mild to moderate spinal cord injury.

LITERATURE:

1. Баратова, М. С., Атаева, М. А., Жалолова, В. З., & Рахматова, М. Р. (2016). Эффективность тиотриазолина при аритмиях. Вестник Совета молодых учёных и специалистов Челябинской области, 1(2 (13)), 4-6.
2. Baratova, M. S., Ataeva, M. A., Yuldasheva, S. T., & Vohidov, U. G. (2020). Periodontal diseases in military age persons and arterial hypertension. Asian Journal of Multidimensional Research (AJMR), 9(4), 111-113.
3. Баратова, М., Атаева, М., Мансурова, М., Кобилова, Г., & Махмудова, М. (2016). Допплерографии в диагностике нарушений функции миокарда лж у больных с высоким нормальным артериальным давлением и мягкой артериальной гипертензией после перенесенных инфекционных состояний. Журнал вестник врача, 1(2), 13-15.
4. Atayeva, M. A., Jarylkasynova, G. J., & Baratova, M. S. (2020). Assesment of heart rhythm disorders at left atrial stanning at early stages of left ventricular modeling. Journal of Critical Reviews JCR, 7(4), 1695-1699.
5. Ataeva, M. A., & Baratova, M. (2021). Diagnosis of heart rhythm disorders at early stages of left ventricular remodeling. Central Asian Journal of Medical and Natural Science, 2(3), 107-112.
6. BARATOVA, M. S., ATAYEVA, M. A., & HALIMOVA, D. S. (2020). Modern Ultrasound Methods for Assessing Indicators of The Latent Diastolic Function of The Left Ventricle. International Journal of Pharmaceutical Research (09752366), 12(3).
7. Баратова, М. С., & Атаева, М. А. (2015). Оценка ранней дисфункции миокарда у больных с пороговой артериальной гипертензий и артериальной гипертензией I-степени. Международный журнал прикладных и фундаментальных исследований, (8-2), 232-233.
8. Субидиновна, Б.М. (2021). Социальные и медицинские аспекты диастолической дисфункции левого желудочка при артериальной гипертензии. Американский журнал медицинских наук и фармацевтических исследований , 3 (09), 14-20.
9. Baratova, M. S. (2021). Algorithm and ultrasonic indicators of stanning of the left atrial in diastolic dysfunction of the left ventricular. European Journal of Research Development and Sustainability, 2(6), 79-83.
10. Baratova, M. (2020). M Makhmudova Predictors of sudden death in patients with arterial hypertension. Recent Scientific Investigation, 695-697.
11. Баратова, М. С., & Атаева, М. А. (2018). РОЛЬ ОРВИ И ГРИППА В ФОРМИРОВАНИИ ОСЛОЖНЕНИЙ СЕРДЕЧНО-СОСУДИСТЫХ ЗАБОЛЕВАНИЙ. Редакционная коллегия, 35.
12. Баратова, М. С., Атаева, М. А., & Махмудова, М. Р. (2021). Диагностика коронавирусной инфекции при сердечно-сосудистой патологии и особенности течения карантина при Covid-19. Биология и интегративная медицина, (3 (50)), 47-66.
13. Baratova, M. S. (2020). Respiratory Viral Infections in the Formation of Left Atrial Standing and Its Early Diagnostics. American Journal of Medicine and Medical Sciences–2020.-10 (4). P, 269-272.
14. Ganju, S. A., & Goel, A. (2000). Prevalence of HBV and HCV infection among health care workers (HCWs). The Journal of communicable diseases, 32(3), 228-230.
15. Baratova, M. S., Ataeva, M. A., & Berdiev, U. A. (2022). Sars and Influenza in the Formation of Complications Heart Rhythmt. AMALIY VA TIBBIYOT FANLARI ILMIIY JURNALI, 1(2), 15-20.

16. Баратова, М., Атаева, М., Мансурова, М., Кобилова, Г., & Махмудова, М. (2016). Допплерографии в диагностике нарушений функции миокарда лж у больных с высоким нормальным артериальным давлением и мягкой артериальной гипертензией после перенесенных инфекционных состояний. Журнал вестник врача, 1(2), 13-15.
17. Баратова, М., Атаева, М., Мансурова, М., Сулейманов, С., Давлетова, С., Узакова, Н., & Суюнова, М. (2013). Дисплазия митрального клапана и её медикаментозное лечение. Журнал проблемы биологии и медицины, (1 (72)), 22-23.
18. Баратова, М., Атаева, М., Якубов, Ш., Мансурова, М., Саъдуллаева, Г., & Кобилова, Г. (2011). Оценка гемодинамических показателей у пациентов с синдромом дисплазии соединительной ткани сердца. Журнал вестник врача, 1(2), 55-56.
19. Баратова, М. С., Бакаев, И. К., Атаева, М. А., & Махмудова, М. Р. 1Баратова Мехрибан Субидиновна/Baratova Mehriban–кандидат медицинских наук, отделение кардиологии; 2Бакаев Илхом Курбанович/Bakaev Ikhom–главный врач, Бухарский областной кардиологический диспансер; 3Атаева Машхура Абборовна/Ataeva Mashkhura–кандидат медицинских наук. EUROPEAN RESEARCH: INNOVATION IN SCIENCE, EDUCATION AND TECHNOLOGY, 102.
20. Баратова, М. С., Кличев, А. Х., Атаева, М. А., & Собиров, С. Н. (2017). Применение тиотриазолина при суправентрикулярных и желудочковых экстрасистолах у пациентов с высоким нормальным артериальным давлением и мягкой артериальной гипертензией после перенесенных инфекционных состояний. V съезд терапевтов Забайкальского края, 14-15 марта 2017 года, г. Чита [Электронный ресурс}: сборник научных трудов/Под общей ред. НВ Ларёвой; Читинская государственная медицинская академия.-Электрон. текстовые дан.-Чита: РИЦ ЧГМА, 2017.-1 электрон. опт. диск (CD-ROM)-Мин. систем. требования: IBM PS 100 МГц; 16 Мб RAM; Windows XP; AdobeReader Сборник содержит статьи и тезисы докладов работников Читинской государственной медицинс, 32.
21. Баратова, М. С. (2022). оценка нарушения ритма сердца при станнинге левого предсердия на ранних этапах ремоделирования левого желудочка. Ijtimoiy fanlarda innovasiya onlayn ilmiy jurnali, 2(1), 182-186.
22. Baratova, M. S. (2023). THE SIGNIFICANCE OF INDICATORS OF DAILY MONITORING OF BLOOD PRESSURE (DMBP-SMAD) IN YOUNG PEOPLE WITH ARTERIAL HYPERTENSION. Новости образования: исследование в XXI веке, 1(9), 1519-1526.
23. Baratova, M. S., Ataeva, M. A., & Zhalolova, V. Z. (2016). The effectiveness of thiotrizoline in arrhythmias. Bulletin of the Council of Young Scientists and Specialists of the Chelyabinsk Region, 1(2 (13)).
24. Баратова, М. С., & Хидоятова, М. Р. (2022). Структурно-Геометрические Показатели Левого Желудочка И Левого Предсердия При Нарушения Ритма Сердца. AMALIY VA TIBBIYOT FANLARI ILMIIY JURNALI, 194-199.
25. Баратова, М. С., & Мусаева, Д. М. (2022). Гемодинимические изменения левого желудочка и левого предсердия при артериальной гипертензии. Integrative dentistry and maxillofacial surgery, 1(2), 219-223.
26. Subidinovna, B. M. (2022). Diagnostics of myocardial «stunned» of the left atrial in latent diastolic dysfunction of the left ventricular. Биология и интегративная медицина, (2 (55)), 31-44.
27. Баратова, М. С. (2023). Применение Тиотриазолина При Пароксизмальных Тахикардиях У Пациентов С Гипертонической Болезнью. Research Journal of Trauma and Disability Studies, 2(3), 22-34.

28. Баратова, М. С. (2023). НЕИНВАЗИВНАЯ ДИАГНОСТИКА ЭЛЕКТРИЧЕСКОЙ НЕСТАБИЛЬНОСТИ МИОКАРДА ПРИ АРТЕРИАЛЬНОЙ ГИПЕРТЕНЗИИ. JOURNAL OF INNOVATIONS IN SCIENTIFIC AND EDUCATIONAL RESEARCH, 6(11), 28-32.
29. Baratova, M. S., & Mukhamedova, M. M. (2023). REMODELING OF THE LEFT VENTRICLE AND ATRIUM IN ARTERIAL HYPERTENSION. Новости образования: исследование в XXI веке, 2(13), 307-315.
30. Баратова, М. С., & Холмурадов, Ж. И. (2023). Диагностическое Значение Натрий Уретического Пептида При Артериальной Гипертензи. Central Asian Journal of Medical and Natural Science, 4(2), 146-154.
31. Баратова, М. С. (2022). Показатели ремоделирования левого желудочка и левого предсердия на ранних этапах. Integrative dentistry and maxillofacial surgery, 1(2), 224-227.
32. Baratova, M. S., & Rizaeva, M. J. (2022). DIAGNOSIS OF PAROXYSMAL RHYTHM DISTURBANCES IN YOUNG PEOPLE WITH ARTERIAL HYPERTENSION. NeuroQuantology, 20(10), 5542.
33. Баратова, М. С. (2021). Особенности Ранней Дисфункции И Ремоделирования Миокарда При Covid-19. Central Asian Journal of Medical and Natural Science, 59-63.
34. Baratova, M. S. (2024). LEFT ATRIAL REMODELING AS A MARKER RHYTHM DISORDERS IN ARTERAL HYPERTENSION. Новости образования: исследование в XXI веке, 2(19), 24-32.
35. Баратова, М. С. (2023). ОЦЕНКА ТУРБУЛЕНТНОСТИ РИТМА ПРИ ПРИМНЕНЕНИИ ТИОТРИЗОЛИНА У ПАЦИЕНТОВ С ВЫСОКО НОРМАЛЬНЫМ АРТЕРИАЛЬНЫМ ДАВЛЕНИЕМ. Научный Фокус, 1(6), 495-503.
36. Баратова, М. С. (2023). ОЦЕНКА ПОКАЗАТЕЛЕЙ ЛАТЕНТНОЙ ДИАСТОЛИЧЕСКОЙ ФУНКЦИИ ПРИ ГИПЕРТОНИЧЕСКОЙ БОЛЕЗНИ. Новости образования: исследование в XXI веке, 2(13), 316-323.
37. Баратова, М. С., & Атаева, М. А. (2023). ПРОГНОЗ НАРУШЕНИЙ РИТМА СЕРДЦА ПРИ ГИПЕРТЕНИЧЕСКОЙ БОЛЕЗНИ. AMALIY VA TIBBIYOT FANLARI ILMIY JURNALI, 2(3), 96-103.
38. Баратова, М. С. (2022). ТИОТРИАЗОЛИН ПРИ СУПРАВЕНТРИКУЛЯРНЫХ, ЖЕЛУДОЧКОВЫХ ЭКСТРАСИСТОЛАХ И ФИБРИЛЯЦИИ ПРЕДСЕРДИЙ У ПАЦИЕНТОВ С АРТЕРИАЛЬНОЙ ГИПЕРТЕНЗИЕЙ. IJTIMOIY FANLARDA INNOVASIYA ONLAYN ILMIY JURNALI, 2(1), 173-181.
39. Баратова, М. С. (2021, May). ХРОНОТЕРАПИИ И ХРОНИБИОЛОГИЧЕСКАЯ ХАРАКТЕРИСТИКА НАРУШЕНИЯ РИТМА ПРИ СТАННИНГЕ ЛЕВОГО ПРЕДСЕРДИЯ. In II Международная онлайн научно-практическая конференция «АКТУАЛЬНЫЕ ВОПРОСЫ ФАРМАКОЛОГИИ: ОТ РАЗРАБОТКИ ЛЕКАРСТВ ДО ИХ РАЦИОНАЛЬНОГО ПРИМЕНЕНИЯ» СБОРНИК ТЕЗИСОВ (p. 30). Universidade Federal do Mato Grosso do Sul.
40. Баратова, М. С., & Атаева, М. А. (2020). ХАРАКТЕРИСТИКА АРТЕРИАЛЬНОЙ ГИПЕРТЕНЗИИ У ЛИЦ ПРИЗЫВНОГО ВОЗРАСТА. Новый день в медицине, (1), 167-171.
41. Баратова, М. С., & Гулова, М. А. (2017). ИЗУЧЕНИЕ ВЛИЯНИЯ МОРФОЛИНИЙ-МЕТИЛ-ТРИАЗОЛИЛ-ТИОАЦЕТАТ (ТИОТРИАЗОЛИН) ПРИ СУПРАВЕНТРИКУЛЯРНЫХ И ЖЕЛУДОЧКОВЫХ ЭКСТРАСИСТОЛАХ. In БОТКИНСКИЕ ЧТЕНИЯ (pp. 20-21).
42. Баратова, М. С., Файзуллаев, Т. Т., & Тоиров, М. Ш. НОВЫЙ ДЕНЬ В МЕДИЦИНЕ. НОВЫЙ ДЕНЬ В МЕДИЦИНЕ Учредители: Бухарский государственный медицинский институт, ООО" Новый день в медицине", (5), 31-35.